

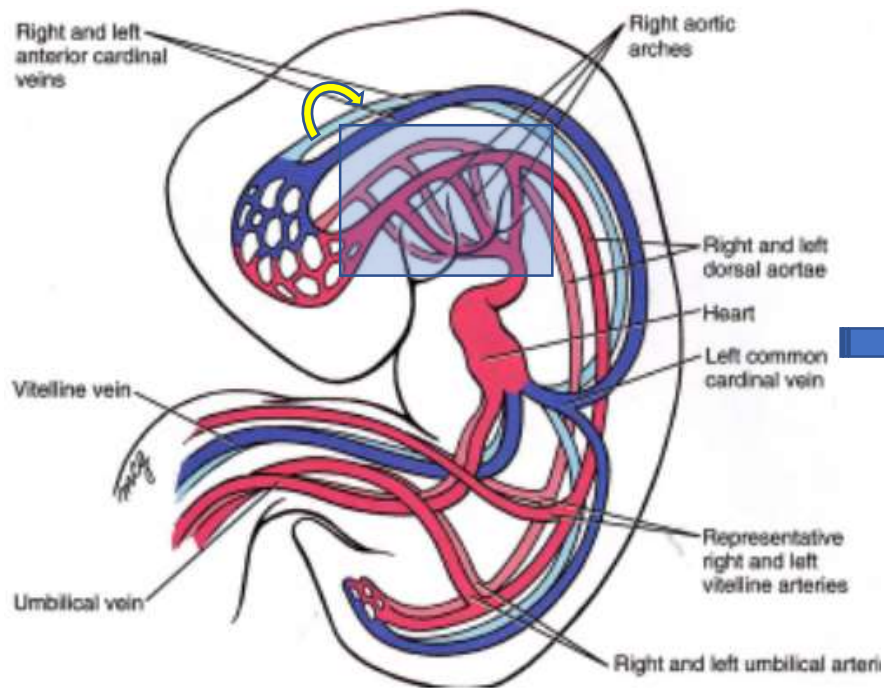
Fetal aortic arch branching variants and anomalies

Yili Zhao, PhD, RDCS, RDMS

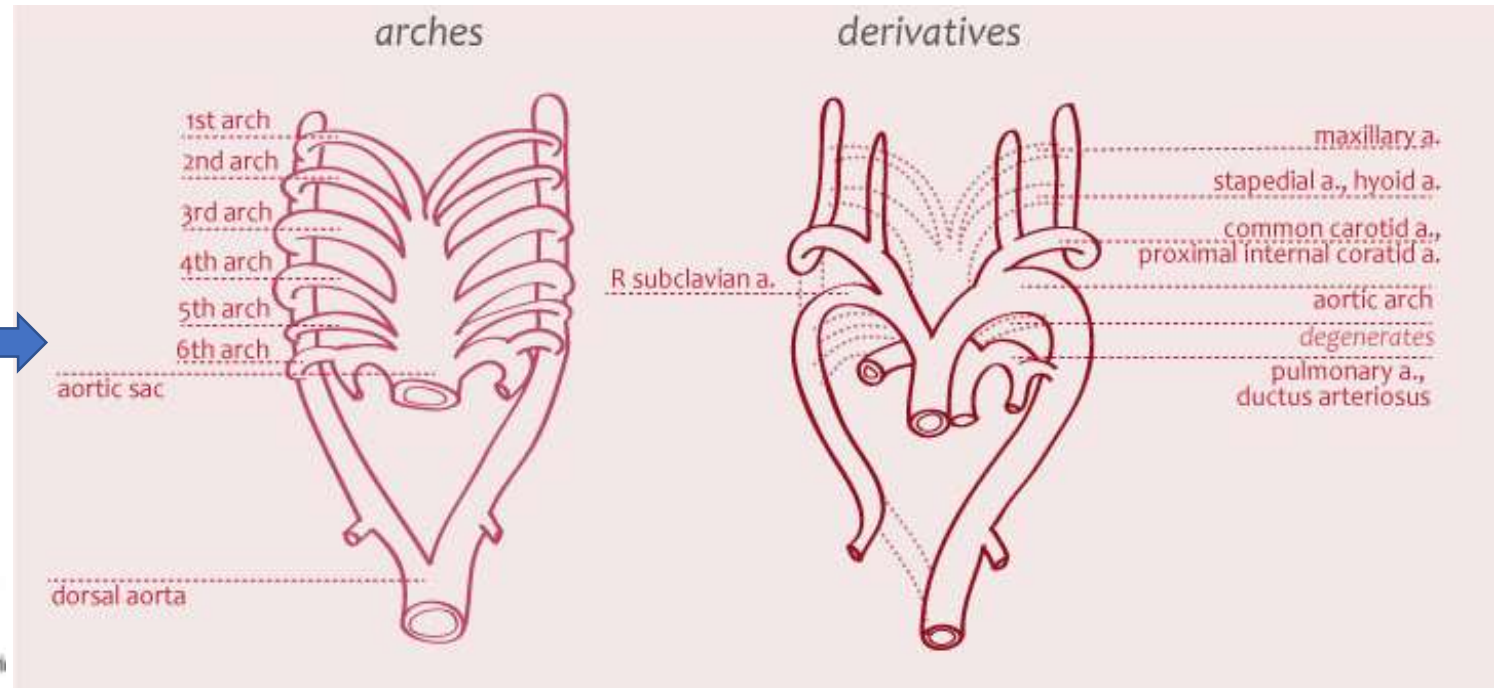
Pediatric Echocardiography, UCSF Benioff Children's Hospital

Embryology

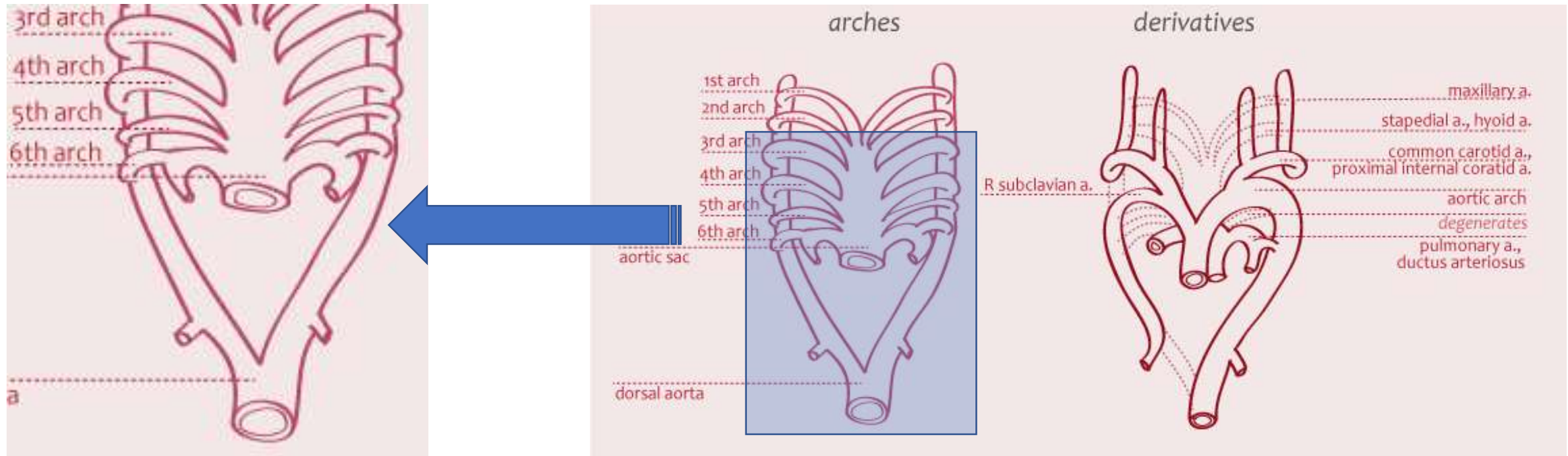
At the 5th week after fertilization







Aortic arches



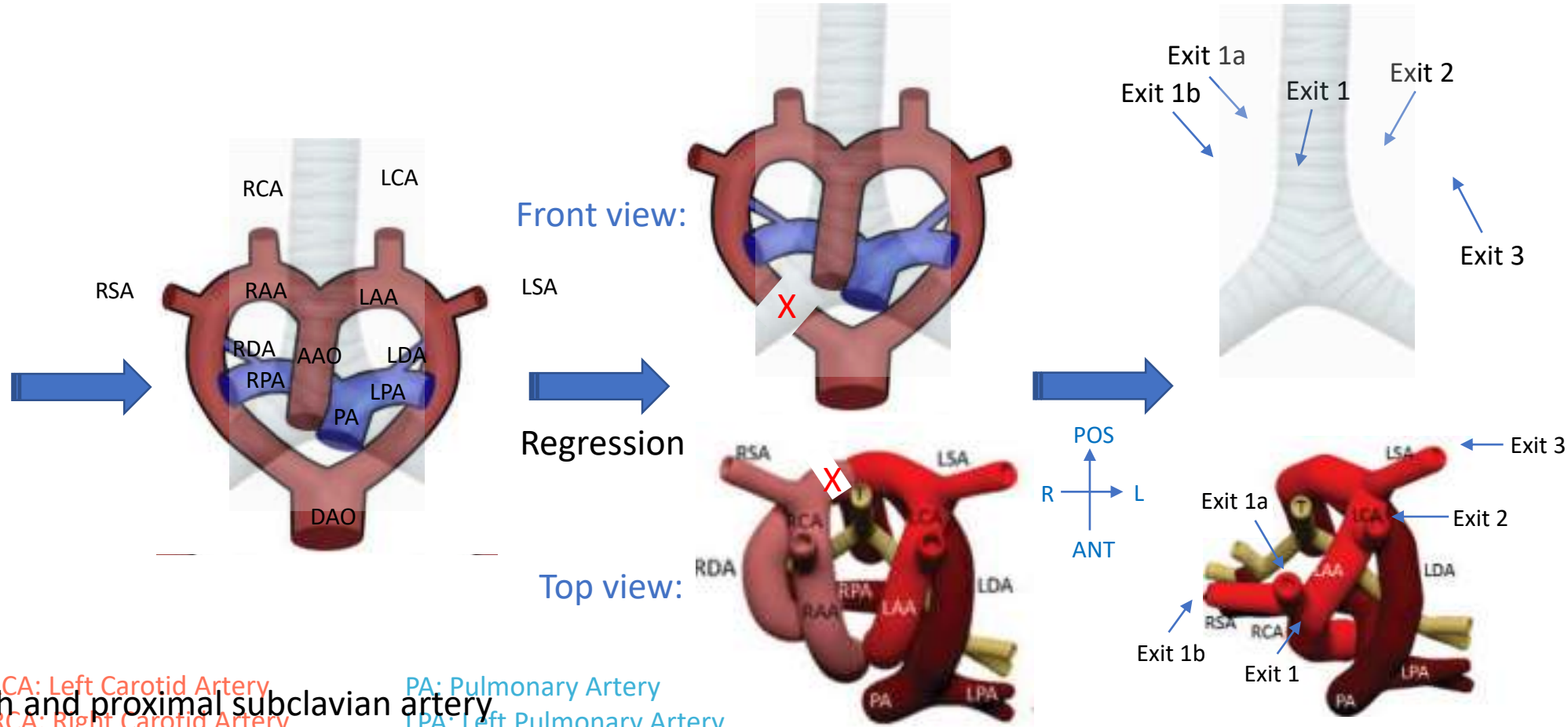
Embryology



-  Future aortic arch and proximal subclavian artery
-  Future carotid arteries
-  Future subclavian arteries
-  Future pulmonary arteries and ductus arteriosus

<https://step1.medbullets.com/embryology/103012/postnatal-derivatives>

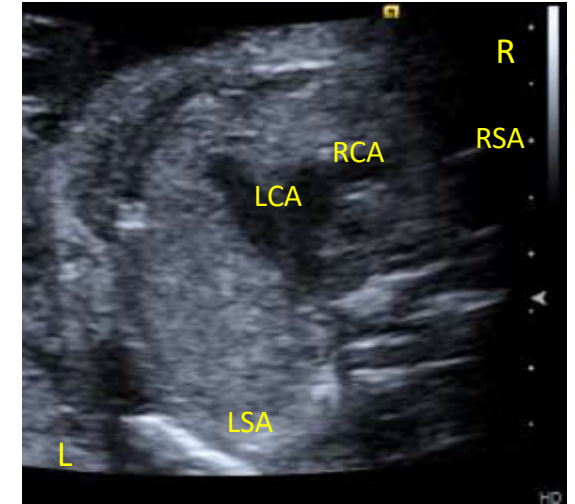
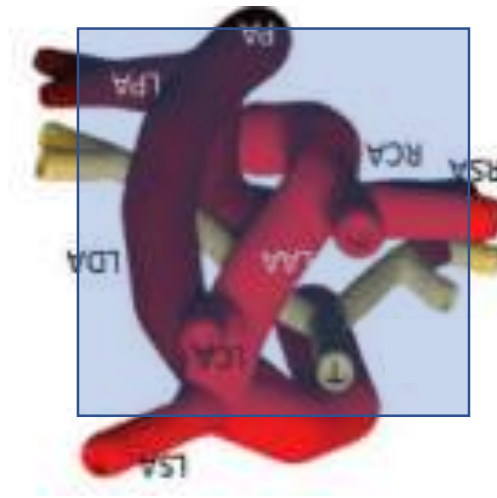
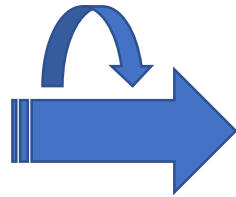
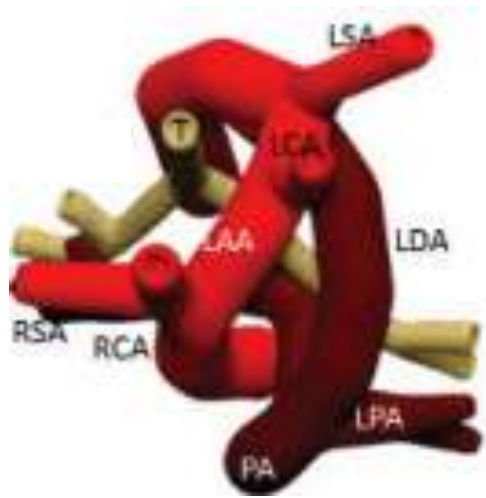
Embryology



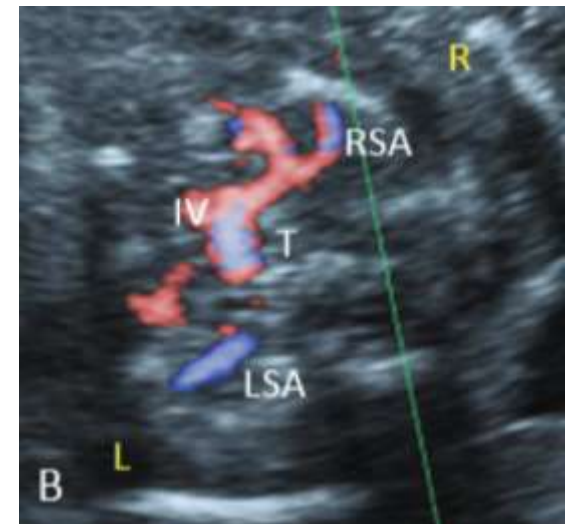- Left Aortic Arch
- Right Aortic Arch
- Ascending Aorta
- Descending Aorta
- Future pulmonary arteries and ductus arteriosus
- LCA: Left Carotid Artery
- RCA: Right Carotid Artery
- LSA: Left Subclavian Artery
- RSA: Right Subclavian Artery
- PA: Pulmonary Artery
- LPA: Left Pulmonary Artery
- RPA: Right Pulmonary Artery
- LDA: Left Ductus Arteriosus
- RDA: Right Ductus Arteriosus

Wang Y, et al. Strategies for Accurate Diagnosis of Fetal Aortic Arch Anomalies: Benefits of Three-Dimensional Sonography With Spatiotemporal Image Correlation and a Novel Algorithm for Volume Analysis. *J Am Soc Echocardiogr.* 2018 Nov;31(11):1238-1251.

Normal fetal echocardiogram



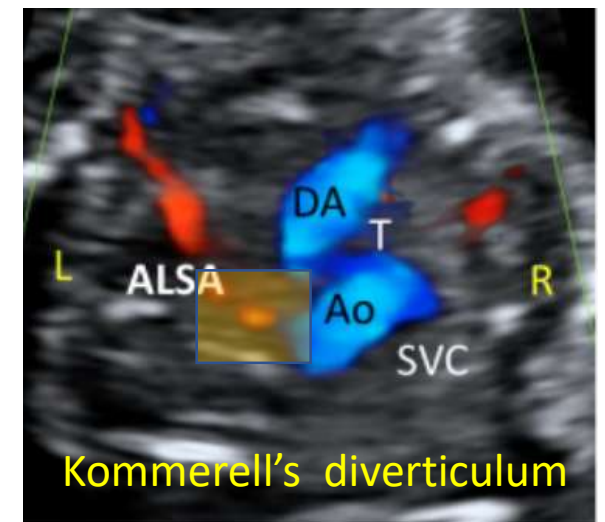
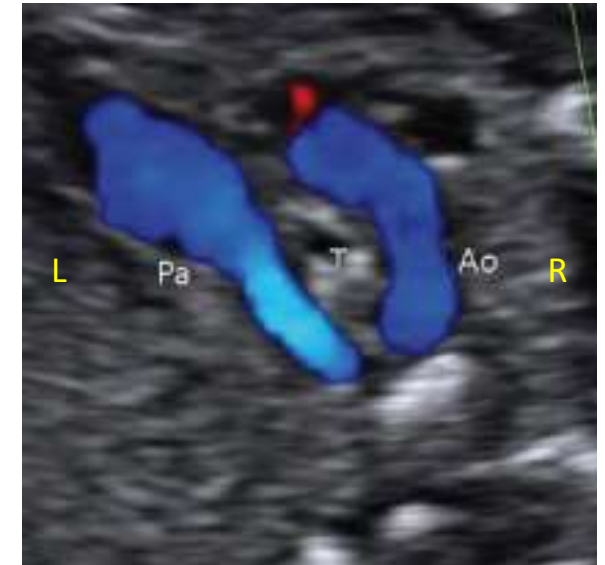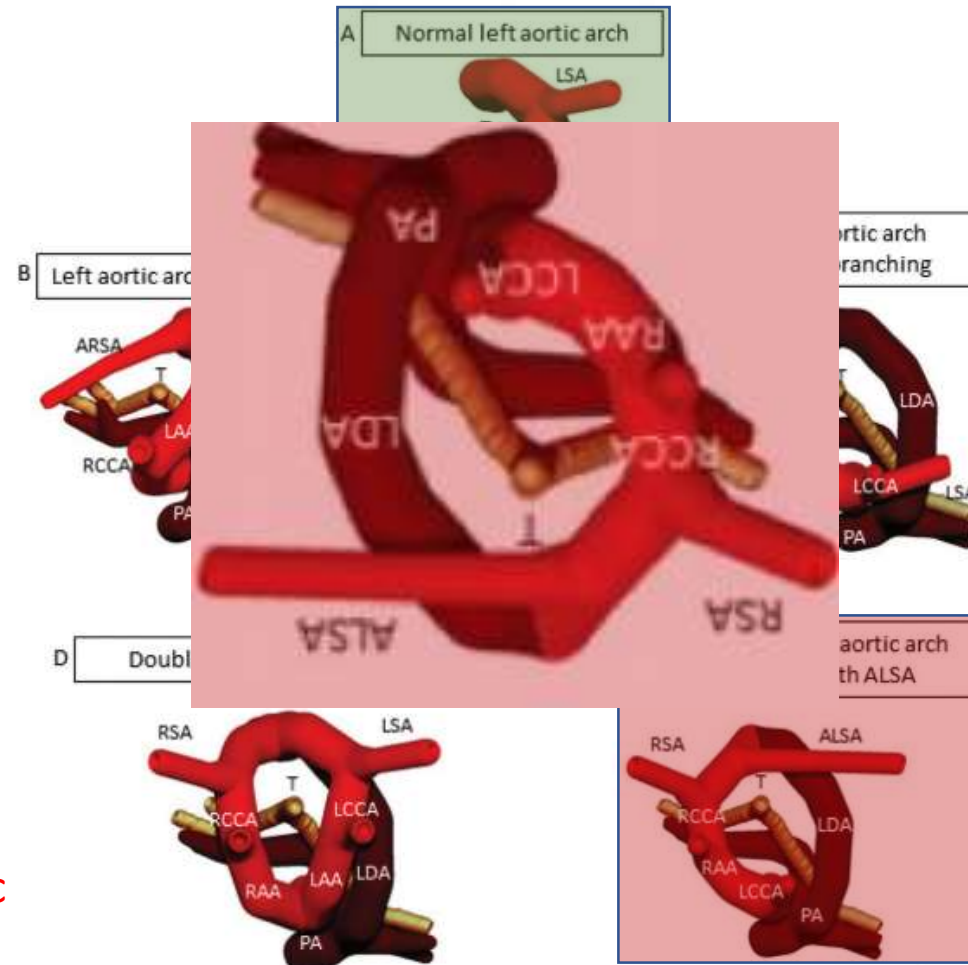
3VT view: "V" shape



Bravo C, et al. Fetal Aortic Arch Anomalies: Key Sonographic Views for Their Differential Diagnosis and Clinical Implications Using the Cardiovascular System Sonographic Evaluation Protocol. *J Ultrasound Med.* 2016 Feb;35(2):237-51.

Aortic arch branching anomalies

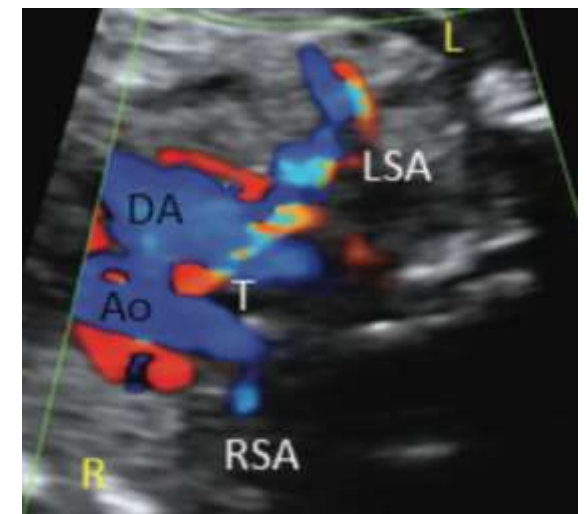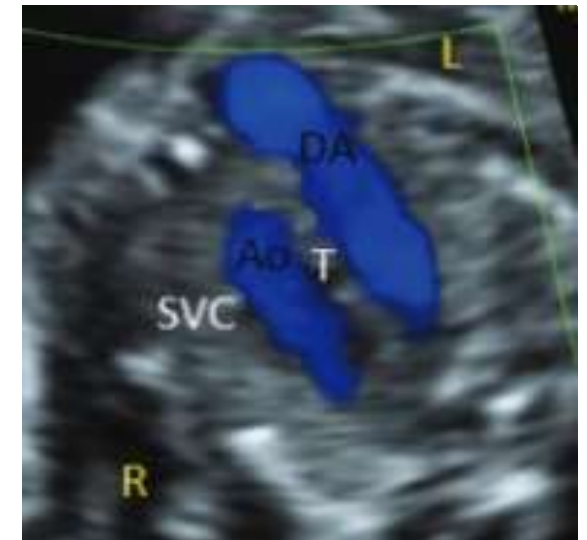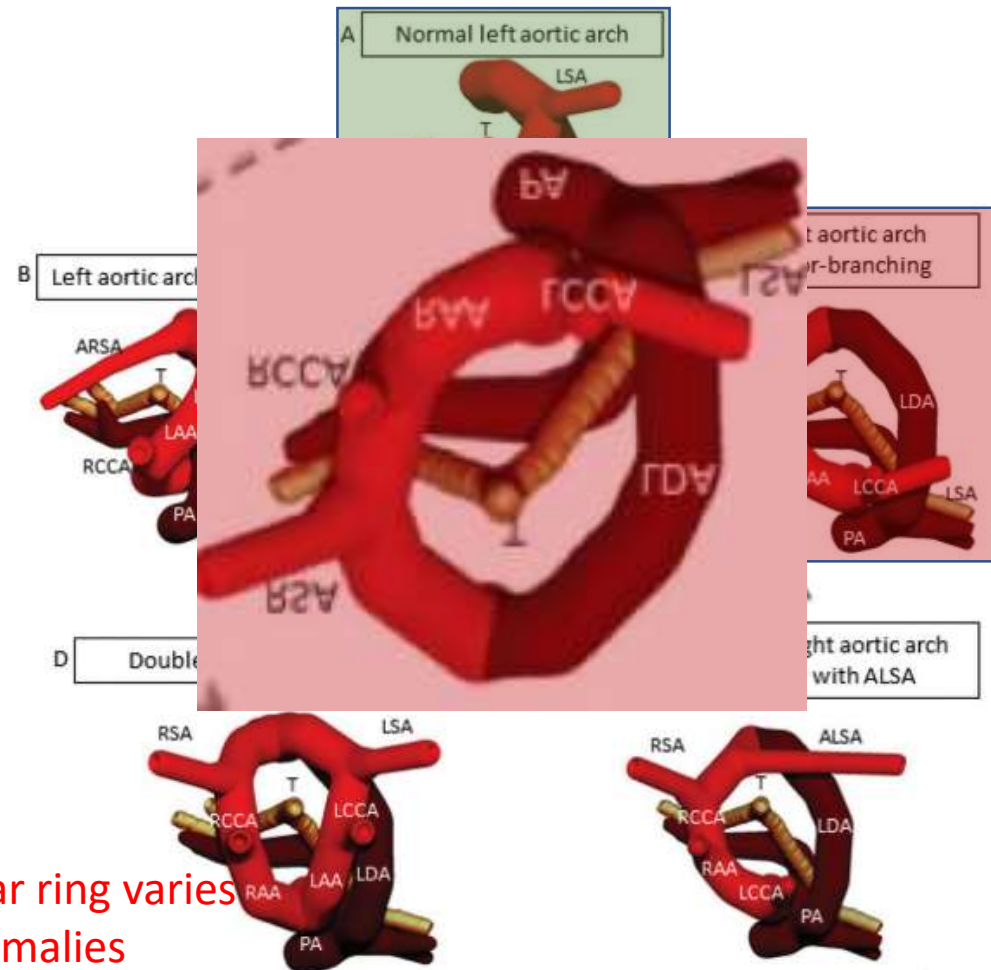
- Left Sided Aortic Arch
 - Left sided arch with aberrant right subclavian artery
- Right Sided Aortic Arch
 - Right sided arch with aberrant left subclavian artery
 - Right sided arch with mirror image branching
 - Left ductus arteriosus
 - Right ductus arteriosus
- Double Aortic Arch
 - “U” shape – Partial ring
 - Median risks for symptomatic vascular ring



<https://www.oatext.com/pdf/JIC-3-227.pdf>

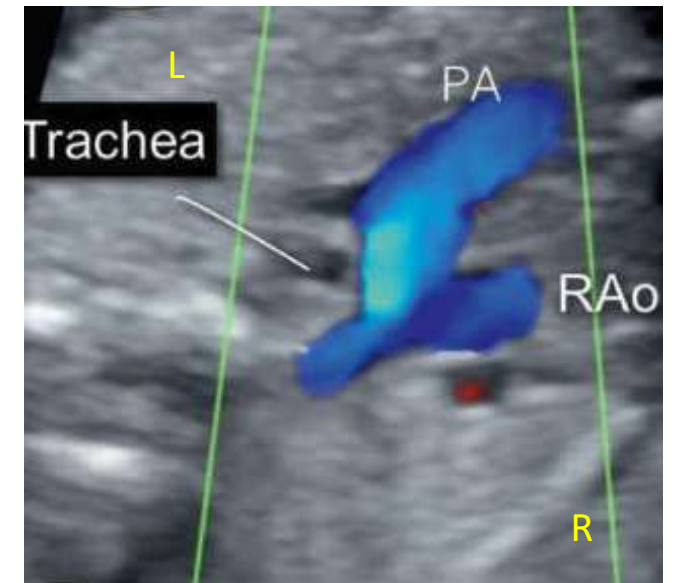
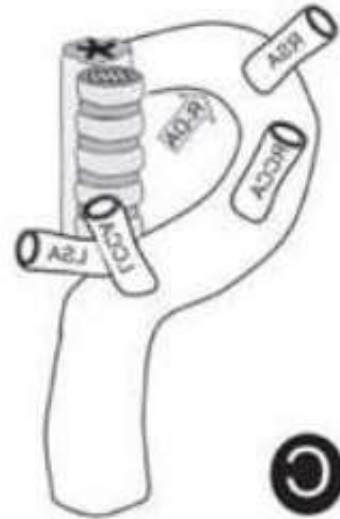Aortic arch branching anomalies

- Left Sided Aortic Arch
 - Left sided arch with aberrant right subclavian artery
- Right Sided Aortic Arch
 - Right sided arch with aberrant left subclavian artery
 - Right sided arch with mirror image branching
 - Left ductus arteriosus
 - Right ductus arteriosus
- Double Aortic Arch
 - “U” or “V” shape
 - Risks for symptomatic vascular ring varies
 - High risks for conotruncal anomalies



Aortic arch branching anomalies

- Left Sided Aortic Arch
 - Left sided arch with aberrant right subclavian artery
- Right Sided Aortic Arch
 - Right sided arch with aberrant left subclavian artery
 - Right sided arch with mirror image branching
 - Left ductus arteriosus
 - Right ductus arteriosus
- Double Aortic Arch

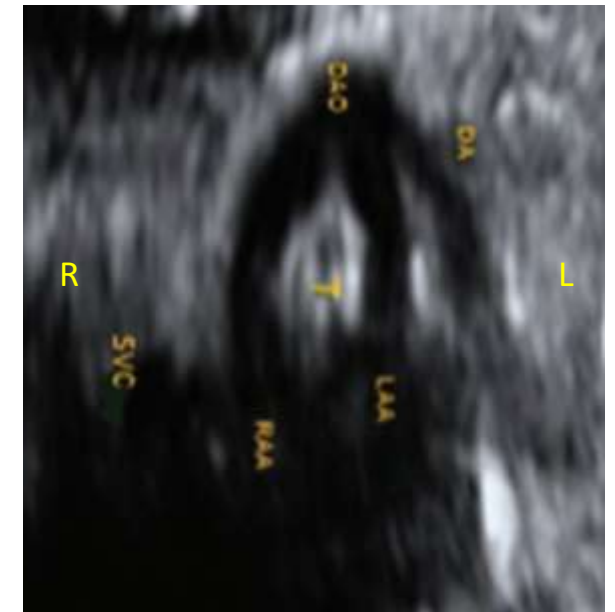
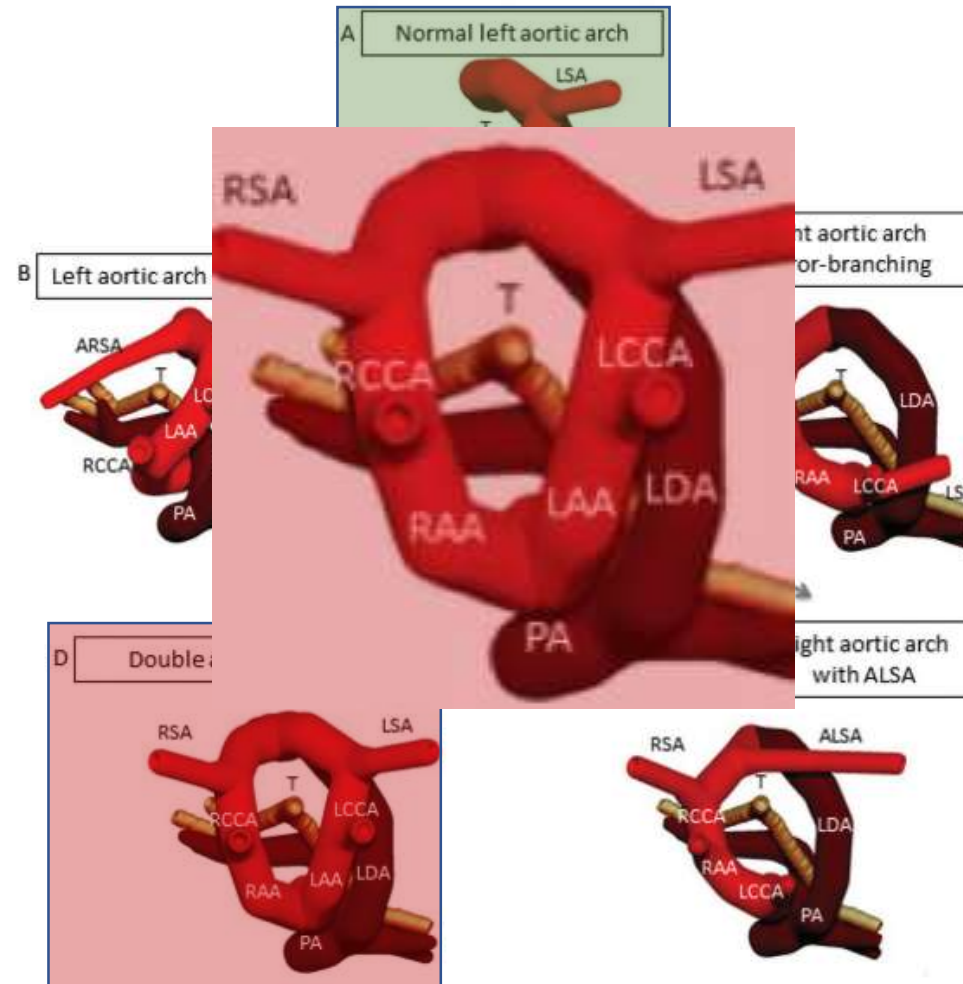


- “V” shape
- No risks for symptomatic vascular ring
- High risks for conotruncal anomalies

Abuhamad A, Chaoui R. *A Practical Guide to Fetal Echocardiography: Normal and Abnormal Hearts*. 3rd Edition. P: 471.

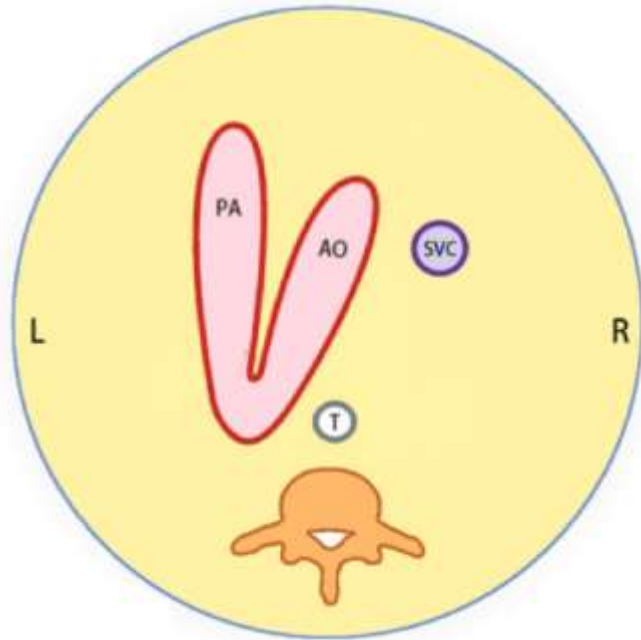
Aortic arch branching anomalies

- Left Sided Aortic Arch
 - Left sided arch with aberrant right subclavian artery
- Right Sided Aortic Arch
 - Right sided arch with aberrant left subclavian artery
 - Right sided arch with mirror image branching
 - Left ductus arteriosus
 - Right ductus arteriosus
- Double Aortic Arch
 - “O” shape – Complete ring
 - High risks for symptomatic vascular ring

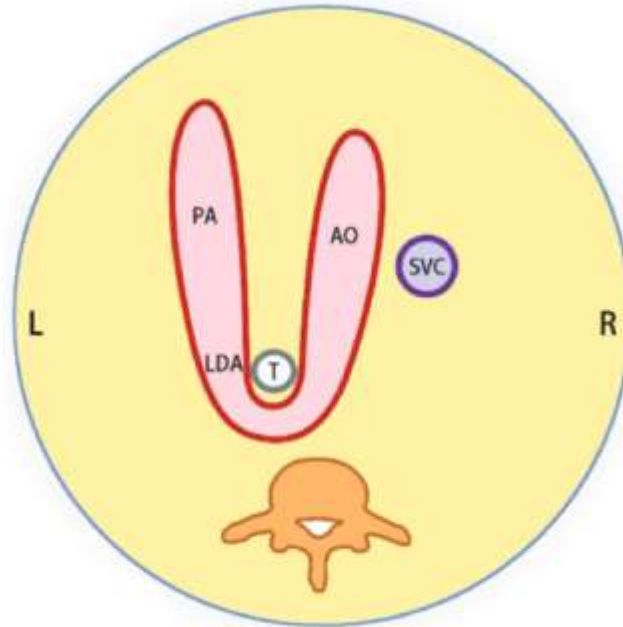


Trobo D, et al. Prenatal Sonographic Features of a Double Aortic Arch: Literature Review and Perinatal Management. J Ultrasound Med. 2015 Nov;34(11):1921-7

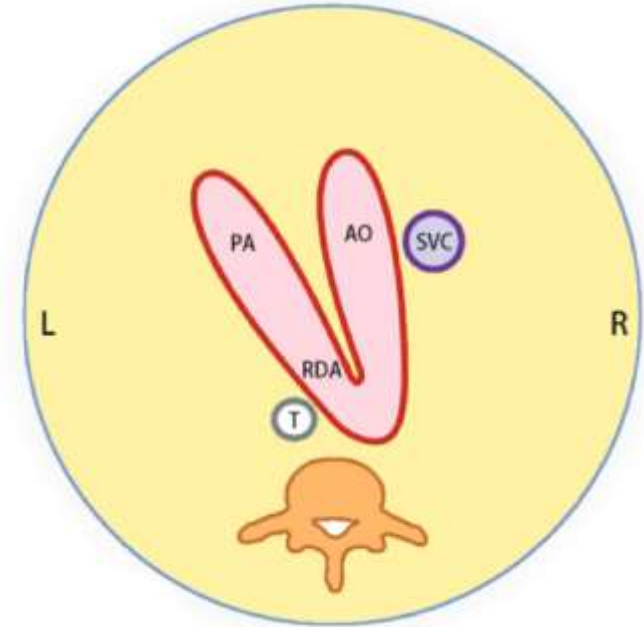
“U” sign vs “V” sign



Normal: LAA + LDA
“V” sign



Abnormal: RAA + LDA
“U” sign



Abnormal: RAA + RDA
Reversed “V” sign

Thank you!